


The Physical Hazards of Foreign Materials

Presentation for the Public Meeting on Foreign Material
Contamination
Sept 24, 2002

David P. Goldman, M.D., M.P.H.
Human Health Sciences Division
Food Safety and Inspection Service



Objectives

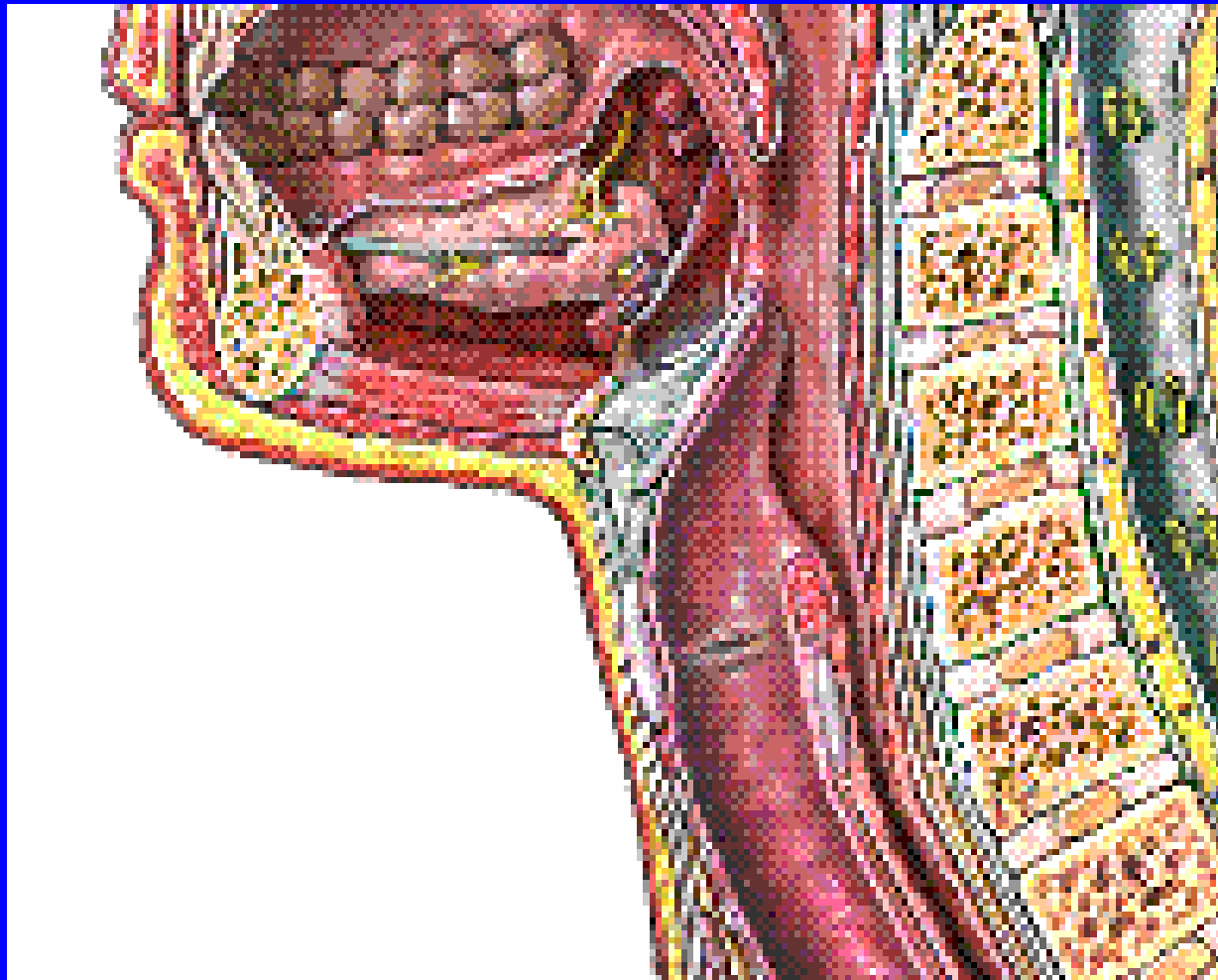
- Describe generally the physical hazards of ingested foreign bodies
- Review epidemiologic and clinical data on foreign body ingestion
- Describe Federal efforts, based on the characteristics of the foreign material, to minimize risks to human health

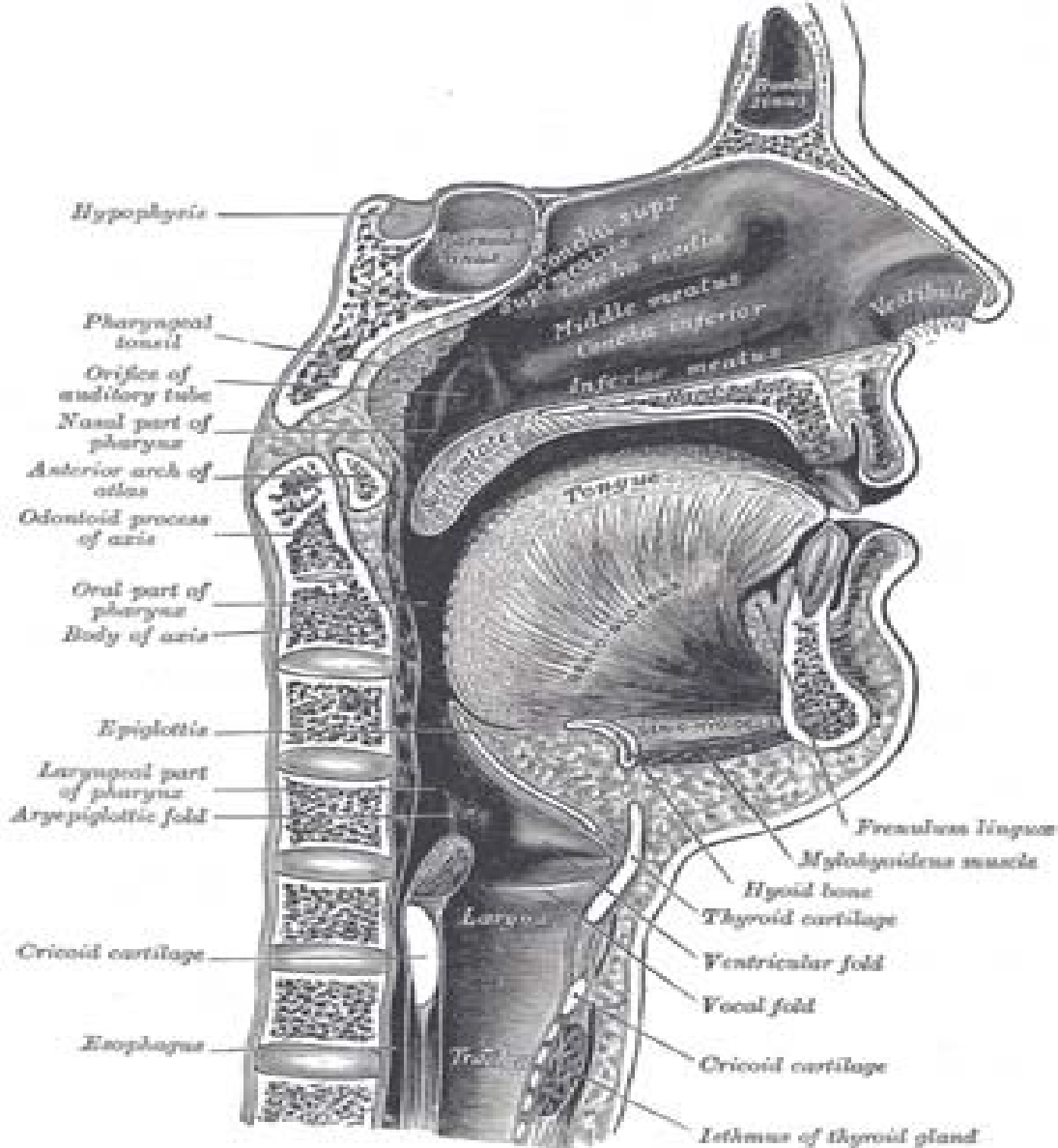
What Parts of the Human Anatomy are at Risk?

- Digestive Tract
- Respiratory Tract
- Mouth and Teeth
- Extremities (Hands)

Hazards to the Digestive Tract

- Esophageal laceration
- Esophageal perforation
- Fistula formation
- Laceration or perforation of other portions of the digestive tract
 - Pharynx
 - Stomach
 - Intestine





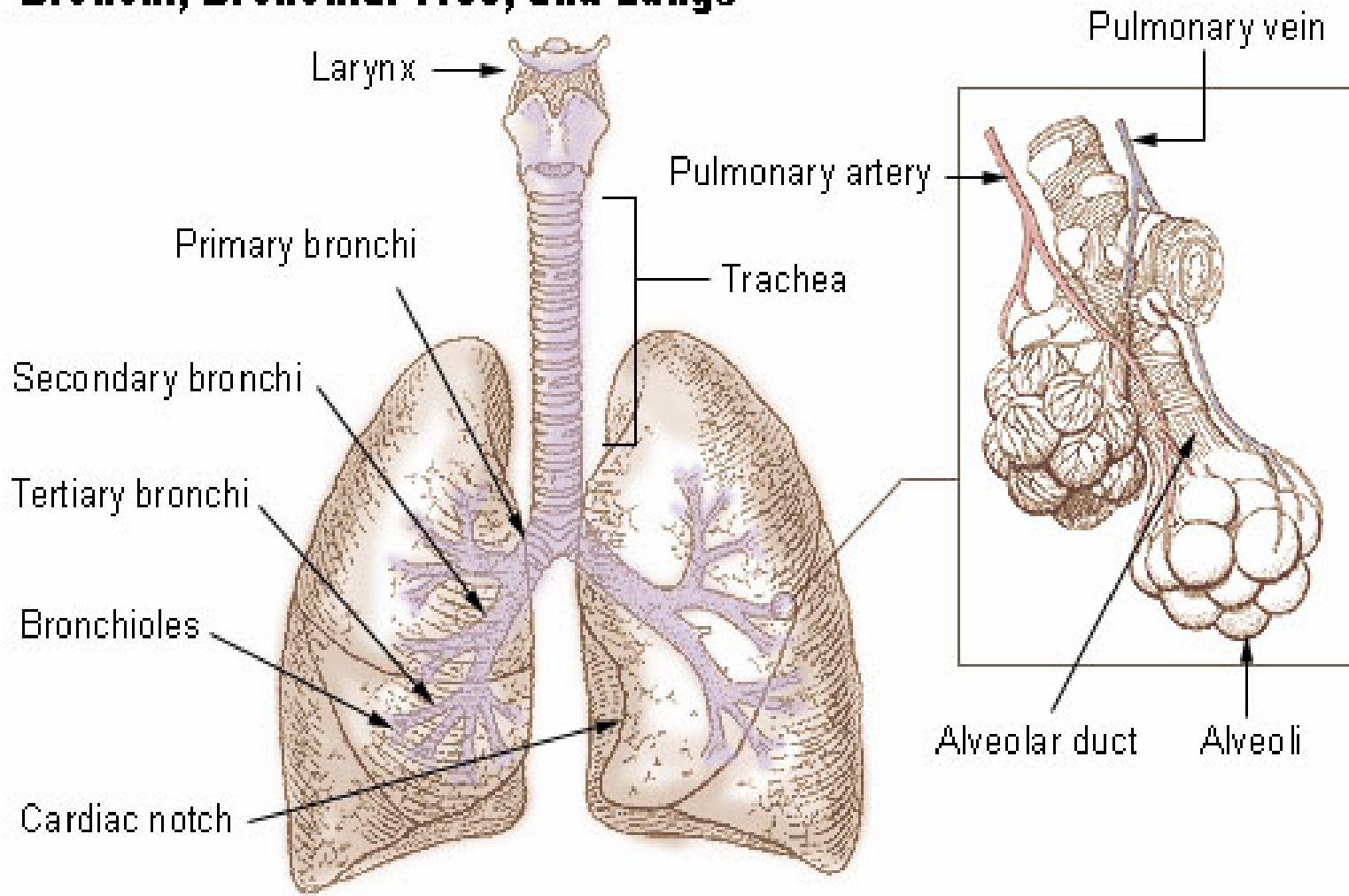
Hazards to the Respiratory Tract

- Choking--occlusion of the airway
 - Children under age 3 at greatest risk
 - Common hazards are foreign objects (coins or toys) or food, *though not foreign objects in food*
 - Objects may become lodged in the upper esophagus and cause choking/asphyxiation by compression of the trachea

Hazards to the Respiratory Tract

- Aspiration--inhalation of foreign matter into the bronchial tree--may result in:
 - partial lung collapse
 - secondary infection
 - destruction of lung tissue from retained material

Bronchi, Bronchial Tree, and Lungs



Hazards to the Mouth and Teeth

- Lacerations of the mouth
- Lacerations of the tongue
- Chipped teeth
- Broken fillings
- Damage to prosthetics

Other Hazards

- Lacerations on the hands occurring during food preparation
- Illness complaints
 - Nausea and vomiting
 - Diarrhea
 - Headache, fever and dizziness
 - Chest pain

Clinical Observations about Foreign Body Ingestion

- About 80% of foreign body (FB) ingestions occur in the pediatric age group
- 80-90% of FBs ingested will pass spontaneously over 4-7 days
- Estimated that 1-5% of FBs ingested will result in injury

Clinical Observations about Foreign Body Ingestion

- Sharp objects account for about 10% of FB ingestions, but a disproportionate number of injuries
- In a case series of foreign bodies removed surgically, 37% were in the airway and 63% were in the upper digestive tract

Clinical Observations about Foreign Body Ingestion

- In a review of FDA consumer complaints of foreign materials in food, the most frequently reported injury was mouth or throat laceration
- In the FDA review glass was the foreign material most frequently reported as causing illness or injury

Characteristics of Foreign Materials that May be Hazardous

Size of the Object

- FSIS in its 1995 Public Health Hazard Analysis Board on bone particles concluded:
 - bone particles < 1 cm not a safety hazard;
 - particles 1-2 cm are a low risk;
 - particles > 2 cm have the potential to be a safety hazard and may cause injury

Characteristics of Foreign Materials that May be Hazardous

Size of the Object

- FSIS (1995): The presence of foreign material other than bone may pose a potential hazard, and each instance should be considered on a case-by-case basis, irrespective of size

Characteristics of Foreign Materials that May be Hazardous

Size of the Object

- Consumer Product Safety Commission (1995): spherical objects < 1.75 inches in diameter are dangerous to children under 3 years (choking, ingestion or aspiration)
- CPSC uses a Small Parts Test Fixture (a cylinder) to judge other non-spherical objects for choking hazard

Characteristics of Foreign Materials that May be Hazardous

Size of the Object

- FDA Health Hazard Evaluation Board conclusions in cases of foreign materials (1972-1997) found that 56% of objects 1-6 mm might pose a limited acute hazard
- For objects > 6 mm, only 2.9% were judged to present no hazard

Characteristics of Foreign Materials that May be Hazardous

Size of the Object

- FDA/ORA Compliance Policy Guide
 - Criteria for direct reference seizure: Hard or sharp objects 7-25 mm and RTE
 - Criteria for recommending legal action :
 - 7-25 mm and requires additional preparation
 - < 7 mm and intended for special-risk group
 - > 25 mm in length

Characteristics of Foreign Materials that May be Hazardous

Shape of the Object

- Spherical or cylindrical shaped objects present a greater risk for choking
- Slender and sharp or pointed objects present a greater risk for laceration or perforation

Characteristics of Foreign Materials that May be Hazardous

Consistency of the Object

- rigid objects (e.g., coins) caused most choking deaths in children 3 years and older
- conforming objects (e.g., balloons) caused more choking deaths in children under age 3 years

Conclusions

- Foreign material contamination does occur in food items
- Injuries have resulted from foreign materials in foods
- Size matters: particles in food that are small are more likely to escape detection, but less likely to cause injury

Contact information:

- **David Goldman, Deputy Director,
Human Health Sciences Division,
OPHS/FSIS/USDA**
- david.goldman@fsis.usda.gov

202-690-6409

